



PATIENT

Rufus Gant

SPECIES

Feline

BREED

DSH

SEX

Male Neutered

AGE

5.9 years

WEIGHT

10.2lbs

INTERPRETED BY

Maggie Machen Lamy,
DVM, DACVIM
(Cardiology)

IMAGING PERFORMED BY

Melinda Persson, DVM

HOSPITAL NAME

At Home Veterinary

REFERRING VET

Dr. Persson

INVOICE

47133

DATE

3/5/26

PRESENTING CLINICAL SIGNS

History: Recheck echo.

-Current medications: Clopidogrel 18.75mg SID, Pimobendan 1.25mg BID.

-Pertinent previous echo findings (9/2025 MML): Suspect UCM. Slight LVE, mild to moderate biatrial dilation. LV: 1.7, LA: 1.6.

ECHOCARDIOGRAM FINDINGS

2D, m-mode, color flow and doppler imaging is available. The left ventricular wall is largely normal in dimension with regions of borderline thickening. No LV dilation with borderline myocardial dysfunction. There is a mildly hyperechoic endocardium consistent with fibrosis. The papillary muscles are hyperechoic. The mitral valve is normal with no MR. The left atrium is mild to moderately dilated and bulbous in appearance. No obvious smoke. The right atrium is mildly dilated. Tricuspid valve is normal with no TR. The right ventricle appears normal. Blood flow through the LVOT is normal in velocity. The RVOT velocity is mildly elevated with a dynamic profile. No pericardial effusion seen. No pleural effusion. No obvious cardiac tumors.

CARDIAC CHART

FELINE CARDIAC PARAMETERS	BODY WEIGHT (kg)	HR (BPM)	IVSd (cm) <small>(Moise, Pipers)</small>	LVIDd (cm) <small>(Moise, Pipers)</small>	LVWd (cm) <small>(Moise, Pipers)</small>	FS (%)	EF (%)
NORMAL PARAMETER	-----	150-240	0.35-0.55	<2 (mean 1.5)	3.5-0.55	35-67	80-100
PATIENT	4.6	NM	0.54	1.5	0.53	40	76
FELINE CARDIAC PARAMETERS	LA/AO (Boon)	LA/AO HEART BASE (Swe) (Abbott)	LA 2D short axis Base view (cm) (Abbott)		LVOT VEL (m/s)	RVOT VEL (m/s)	E max (m/s)
NORMAL	<1.5	<1.3	<1.2		<1.6	<1.3	<0.9
PATIENT	NM	1.6	1.6		0.8	2.0	NM

**Note: All measurements based upon multi-modal images and methods. An average value is reported.*

Adapted from June Boon, Veterinary Echocardiography, 1998

Abbott J & MacLean H JVIM 2006;20: 111-119, Moise et al. Am J Vet Res 47:1476, 1986. Pipers et al. Am J Vet Res 40:882, 1979.

INTERPRETATION OF THE FINDINGS & FURTHER RECOMMENDATIONS

Stable findings. Mild biatrial dilation persists without obvious progression seen. No significant hypertrophy has developed, and the LV dilation is stable to mildly improved. Of some concern, the LV function continues to decline slightly, and monitoring is certainly recommended going forward. No additional issues are seen. The murmur appears begin in origin with a dynamic RVOT obstruction.

Given these findings, continue 2 medications as previously described. No obvious need for additional medications at this time.



PATIENT

Rufus Gant

SPECIES

Feline

BREED

DSH

SEX

Male Neutered

AGE

5.9 years

WEIGHT

10.2lbs

INTERPRETED BY

Maggie Machen Lamy,
DVM, DACVIM
(Cardiology)

IMAGING PERFORMED BY

Melinda Persson, DVM

HOSPITAL NAME

At Home Veterinary

REFERRING VET

Dr. Persson

INVOICE

47133

DATE

3/5/26

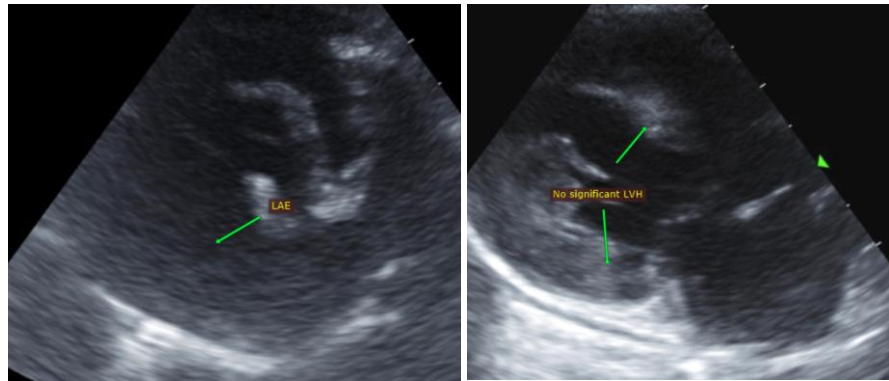
Prognosis remains guarded long-term. There will always remain risk for progression to CHF and development of blood clots and/or sudden death in the future. Monitoring is certainly advised, particularly should any respiratory signs, collapse or significant lethargy be noted in the future.

PLAN

Baseline BP every 6 months. Continue two medications as previously prescribed.

A recheck echocardiogram is recommended in 6-12 months to assess progression.

IMAGES



The information and recommendations provided are based on the images presented by the referring veterinarian. No evaluation can be communicated regarding pathology that was not visible in the image/video clips provided.

Thank you for this referral. This report was generated using transcription software, and minor dictation errors may be present. If the clinical or image interpretation does not parallel your findings or if I can be of any further assistance, please contact me.

Maggie Machen Lamy, DVM

Diplomate of the American College of Veterinary Internal Medicine (Cardiology)

info@sonopath.com